

STUDIES

PCCA PRACASIL™ - PLUS STUDIES & REPORT



Technical Report:

Efficacy of PracaSil™-Plus in scar therapy treatment: a randomized, double-blind, controlled pilot trial



Abstract: The efficacy of PracaSil-Plus in scar therapy treatment was evaluated by visual and instrumental methods in an eight-week, randomized, double-blind, controlled pilot trial. The evaluations were conducted at week zero (baseline) and at week eight. PracaSil-Plus showed qualitative and quantitative improvements in the following scar attributes: scar length, scar color/pigment intensity, scar texture/smoothness/roughness, and overall appearance in both old scars and new scars.

Introduction: PracaSil-Plus is a proprietary anhydrous silicone base designed to be applied topically in scar therapy treatment (PCCA, 2013). Silicones have been widely used for their occlusion and hydration properties, which are essential in scar management (Widgerow *et al.*, 2000; Mustoe, 2008). PracaSil-Plus also contains Pracaxi oil, extracted from the oilseed plant *Pentaclethra macroloba*, which has several medicinal applications including skin regeneration and healing (Costa *et al.*, 2013). PracaSil-Plus may be used alone or as a base for the incorporation of active substances in scar therapy treatment (PCCA, 2013).

Methodology: The efficacy of PracaSil-Plus in scar therapy treatment was evaluated by visual and instrumental methods, in an eight-week randomized, double-blind, controlled pilot trial conducted on eleven adult Caucasian subject volunteers, who were randomly divided in two groups: test group (n=5) and control group (n=6). The test group used PracaSil-Plus and the control group used a standard moisturizer. All subject volunteers had surgical, traumatic or acne-related scarring, either old scar (n=4) (> 18 months) or new scar (n=7) (< 18 months) and were willing to discontinue the use of moisturizing creams and scar-related treatments for the duration of the study. The evaluations were conducted at week zero (baseline) and at week eight, by a specialised IRSI professional.

Materials and Methods: The visual analogue scale (VAS) was the research instrument used in the visual evaluation method. The VAS is an observer-dependent scar assessment scale, designed to assess subjective parameters in an objective way (Fearmonti *et al.*, 2010). In this pilot trial, the subjects' scars were visually graded globally for scar length, scar color intensity and scar texture/smoothness (i) before application of product and (ii) at week eight of application of product (PracaSil-Plus or standard moisturizer).

The Clarity™ Pro and Replica™ were the research instruments used in the instrumental evaluation method.

The Clarity™ Pro is an imaging system that captures images with a hand held scope at 50x in multi-spectral lighting and reveals conditions on the skin's surface layer (Brightex Bio-Photonics, no date). In this pilot trial, the subjects' scars were evaluated with regards to average pigment intensity and texture/smoothness (i) before application of product and (ii) at week eight of application of product (PracaSil-Plus or standard moisturizer).

The Replica™ is a sampling technique specifically designed for making Silastic® (silicone elastomer) casts of the skin surface with the purposes of obtaining skin contour replicas and assessing skin texture (Cuderm, 2003; Dow Corning,

2013). In this pilot trial, skin contour replicas were made of the subjects' scar area and were evaluated with regards to texture/smoothness (i) before application of product and (ii) at week eight of application of product (PracaSil-Plus or standard moisturizer).

Results and Discussion: At week eight of application of PracaSil-Plus, the scars of all subject volunteers were evaluated by both visual and instrumental methods. No adverse reactions were reported, on or around scarring, by any of the subject volunteers.

Visual Analog Scale (VAS): According to the VAS assessment, 20% of test group volunteers showed an improvement in scar length, 40% in scar color intensity and 80% in scar texture/smoothness. On average, scar length was reduced 2.5%, scar color intensity 20% and scar smoothness was increased 24.08% (Table 1).

Table 1. Percentage of test group subjects with improvement and average percentage of improvement in relation to scar length, color intensity and texture/smoothness.

Scar	% subjects (with improvement)	% improvement (from baseline)
Length	20.00%	2.50%
Color intensity	40.00%	20.00%
Texture/ smoothness	80.00%	24.08%

Clarity™ Pro: According to this imaging system, 74.30% of test group volunteers showed an improvement in scar pigment intensity and 100% showed an improvement in scar texture/smoothness. On average, scar pigment intensity was reduced 17.56% whereas texture/smoothness was reduced 22.32% (Table 2).

Table 2. Percentage of test group subjects with improvement and average percentage of improvement in relation to scar pigment intensity and texture/smoothness.

Scar	% subjects (with improvement)	% improvement (from baseline)
Pigment intensity	74.30%	17.56%
Texture/ smoothness	100.00%	22.32%

Technical Report:

Efficacy of PracaSil™-Plus in scar therapy treatment: a randomized, double-blind, controlled pilot trial



The scar images of two test group volunteers (A and B) are displayed in Figure 1 and Figure 2 (respectively). Both figures show evident overall improvements in scar management.

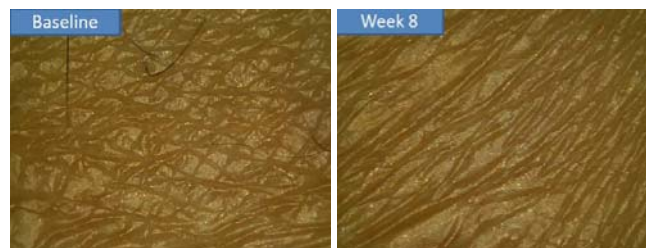

Figure 1. Subject's scar (A) before application of PracaSil-Plus (left) and at week eight of application of PracaSil-Plus (right).



Figure 2. Subject's scar (B) before application of PracaSil-Plus (left) and at week eight of application of PracaSil-Plus (right).

Replica™: The skin contour replicas of two test group volunteers (A and B) are displayed in Figure 3 and Figure 4 (respectively). Both figures show evident overall improvements in scar texture/roughness.

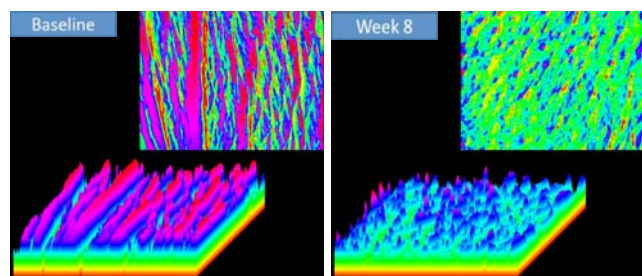


Figure 3. Subject's scar (A) before application of PracaSil-Plus (left) and at week eight of application of PracaSil-Plus (right).

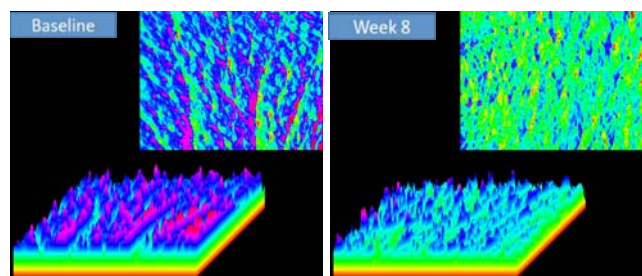


Figure 4. Subject's scar (B) before application of PracaSil-Plus (left) and at week eight of application of PracaSil-Plus (right).

According to this sampling technique, 100% of test group volunteers showed an improvement in scar texture/roughness, which was reduced, on average, 16.01% (Table 3).

Table 3. Percentage of test group subjects with improvement and average percentage of improvement in relation to scar texture/roughness.

Scar	% subjects (with improvement)	% improvement (from baseline)
Texture/roughness	100.00%	16.01%

Conclusions: PracaSil-Plus, a proprietary base constituted by silicones and Pracaxi oil, showed qualitative and quantitative improvements in the following scar attributes: scar length, scar color/pigment intensity, scar texture/smoothness/roughness and overall appearance in both old scars and new scars. PracaSil-Plus is therefore recommended in scar therapy treatment, to be used alone or as a base for the incorporation of active substances.

Financial Disclosure: PCCA contracted the International Research Services, Inc. (ISRI, Port Chester, NY) to conduct this study. ISRI has no proprietary or financial interests in the test products, or equity interest in PCCA, the sponsor of the study.

References:

- Brightex Bio-Photonics (no date) *Advanced skin analysis: Clarity Pro*. Available at: http://www.btbp.org/Downloads/BTBP_CPbrochure2_web.pdf (Accessed: 15 July 2013).
- Costa, M., Muniz, M., Negrao, C., Costa, C., Lamarao, M., Morais, L., Junior, J. and Costa, R. (2013) 'Characterization of *Pentaclethra macroloba* oil', *Journal of Thermal Analysis and Calorimetry*, 16 January 2013 [Online].
- Cuderm (2003) *Replica*. Available at: http://cuderm.com/products_replica_rd.php (Accessed: 13 July 2013).
- Dow Corning (2013) *Silicone elastomers*. Available at: <http://www.dowcorning.com/content/rubber/> (Accessed: 13 July 2013).
- Fearmonti, R., Bond, J., Erdmann, D. and Levinson, H. (2010) 'A review of scar scales and scar measuring devices', *ePlasty*, 21 June 2010 [Online].
- Mustoe, T. (2008) 'Evolution of silicone therapy and mechanism of action in scar management', *Aesthetic Plastic Surgery*, 32 (1), p.82-92.
- PCCA (2013) *PracaSil-Plus*. Available at: <http://www.pccarx.com/pcca-products/pcca-exclusives/bases/pracasil-plus> (Accessed: 17 May 2013).
- Widgerow, A., Chait, L., Stals, R. and Stals, P. (2000) 'New innovations in scar management', *Aesthetic Plastic Surgery*, 24 (3), p.227-234.



Click the QR to see more PCCA studies and reports.

Case Study: Ankle Scars (Old & New)



PCCA PracaSil™-Plus

Summary: PracaSil-Plus, a proprietary anhydrous silicone base, was applied topically on ankle scars (old & new) and an overall improvement of both ankle scars was observed in a very short period of time.

Case Description (1): A type 1 diabetic 57-year-old woman fractured her ankle during a ski accident in March 2009. The patient underwent three reconstructive surgeries between 2009 and 2012, which resulted in three ankle scars. After the application of different products, the patient was still unsatisfied with the resulting unaesthetic scars. In April 2013, it was suggested the patient apply PracaSil-Plus twice daily on the old scars. Figures 1 and 2 (below) show the overall appearance of one of the patient's old scars, before (left) and one week after (right) the application of PracaSil-Plus.

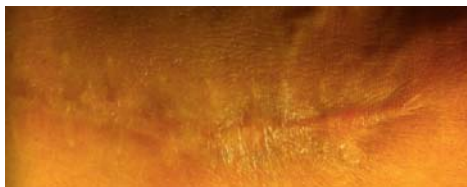

Figure 1. Patient old ankle scar (before PracaSil-Plus)

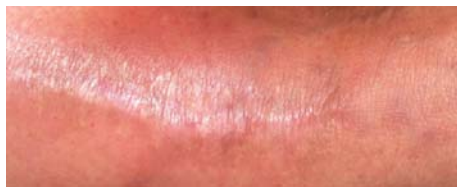

Figure 2. Patient old ankle scar (one week after PracaSil-Plus)

Patient Report: *In only one week I had incredible improvements in the overall appearance of my scars. The thickness almost completely disappeared, the dark color faded and the skin softened. I am very impressed with the results obtained.*

Case Description (2): A 50-year-old woman diagnosed with osteochondritis dissecans of the right talus went in for osteochondral allograft surgery, for the second time, in March 2013. The patient was advised to wait 10 days, following the removal of the stitches, before applying any topical scar treatments. After this period, the patient initiated treatment with (only) PracaSil-Plus twice daily for two weeks, lightly massaging into and around the scar area. Figures 3 and 4 (below) show the overall appearance of the patient's new scar, before (left) and two weeks after (right) the application of PracaSil-Plus.

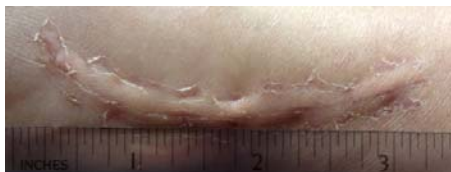


Figure 3. Patient new ankle scar (before PracaSil-Plus)

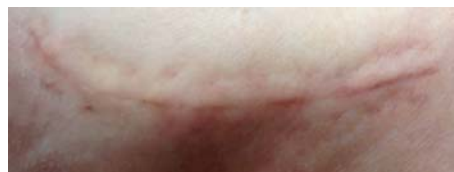

Figure 4. Patient new ankle scar (two weeks after PracaSil-Plus)

Patient Report: *The results have been fantastic. The scar is very smooth and it has reduced in size over time. At the end of two weeks, the scar was considerably flattened and wearing a sock did not irritate the area.*

Acknowledgements: Both patients agreed to anonymously share the information and figures included in this case study. Figures 1 - 4 are courtesy of the patients. PCCA Science is grateful for the valuable information shared.

Introduction: PracaSil-Plus is a proprietary anhydrous silicone base designed to be applied topically in scar therapy treatment (PCCA, 2013a). Silicones have been widely used for their occlusion and hydration properties, which are essential in scar management (Widgerow *et al.*, 2000; Mustoe, 2008). PracaSil-Plus also contains Pracaxi oil, extracted from the oilseed plant *Pentaclethra maculoba*, which has several medicinal applications including skin regeneration and healing (Costa *et al.*, 2013). PracaSil-Plus may be used alone or as a base for the incorporation of active substances in scar therapy treatment (PCCA, 2013a).

Research Studies: The efficacy of PracaSil-Plus in scar therapy treatment was evaluated by visual and instrumental methods in an eight-week, randomized, double-blind, controlled pilot trial conducted on eleven adult Caucasian subject volunteers. PracaSil-Plus showed qualitative and quantitative improvements in the following scar attributes: scar length, scar color/pigment intensity, scar texture/smoothness/roughness, and overall appearance in both old scars and new scars (PCCA, 2013b).

References:

- Costa, M., Muniz, M., Negrao, C., Costa, C., Lamarao, M., Morais, L., Junior, J. and Costa, R. (2013) 'Characterization of *Pentaclethra maculoba* oil', *Journal of Thermal Analysis and Calorimetry*, 16 January 2013 [Online].
- Mustoe, T. (2008) 'Evolution of silicone therapy and mechanism of action in scar management', *Aesthetic Plastic Surgery*, 32 (1), p.82-92.
- PCCA (2013a) *PracaSil-Plus*. Available at: <http://www.pccarx.com/pcca-products/pcca-exclusives/bases/PracaSil-plus> (Accessed: 17 May 2013).
- PCCA (2013b) 'Efficacy of PracaSil-Plus in scar therapy treatment: a randomized, double-blind, controlled pilot trial', *Technical Report: 2TR0513*.
- Widgerow, A., Chait, L., Stals, R. and Stals, P. (2000) 'New innovations in scar management', *Aesthetic Plastic Surgery*, 24 (3), p.227-234.



Click the QR to see more PCCA studies and reports.

Case Study: Facial Scars

PCCA PracaSil™-Plus



Summary: A compounded medicine containing PracaSil-Plus (**PCCA Formula #10649**) was applied topically on facial scars (old) and an overall improvement of the facial complexion was observed following only 3 weeks.

Case Description: A 22-year-old female was severely scarred on the face during a car accident in October 2009. After six plastic surgeries and the application of different products, the patient was still unsatisfied with her complexion. In March 2013, PCCA suggested a compounded medicine containing Pentoxifylline 1%, Caffeine 1% and Tranilast 1% in PracaSil-Plus topical gel (Figure 1) to be applied twice a day on the (old) facial scars (Yamada *et al.*, 1994; Nomura *et al.*, 2005; Isaac *et al.*, 2009).

Pentoxifylline USP	1 g
Caffeine USP Anhydrous	1 g
Tranilast	1 g
PCCA PracaSil™-Plus	97 g

Figure 1. PCCA Formula #10649

After 3 weeks of treatment, the patient was surprised by the softening of her skin and overall improvement of her complexion (Figures 2 and 3).

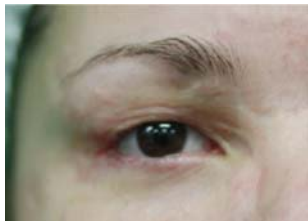

Figure 2. Patient facial scars (before PracaSil-Plus gel)

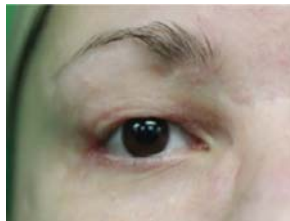


Figure 3. Patient facial scars (after PracaSil-Plus gel)

Patient Report: *I have tried many products with little satisfaction. PracaSil-Plus has shown amazing results in a very short amount of time. PracaSil-Plus reduced the redness of the scars and gave my skin a more uniform look and texture. I am very happy with PracaSil-Plus and I would recommend it to everyone.*

Acknowledgements: The patient is a PCCA staff member who agreed to share the information included in this case study. Figures 2 and 3 are courtesy of the patient. PCCA Science is grateful for the valuable information and figures shared by the patient.

Introduction: PracaSil-Plus is a proprietary anhydrous silicone base designed to be applied topically in scar therapy treatment (PCCA, 2013a). Silicones have been widely used for their occlusion and hydration properties, which are essential in scar management (Widgerow *et al.*, 2000; Mustoe, 2008). PracaSil-Plus also contains Pracaxi oil, extracted from the oilseed plant *Pentaclethra macroloba*, which has several medicinal applications including skin regeneration and healing (Costa *et al.*, 2013). PracaSil-Plus may be used alone or as a base for the incorporation of active substances in scar therapy treatment (PCCA, 2013a).

Research Studies: The efficacy of PracaSil-Plus in scar therapy treatment was evaluated by visual and instrumental methods in an eight-week, randomized, double-blind, controlled pilot trial conducted on eleven adult Caucasian subject volunteers. PracaSil-Plus showed qualitative and quantitative improvements in the following scar attributes: scar length, scar color/pigment intensity, scar texture/smoothness/roughness, and overall appearance in both old scars and new scars (PCCA, 2013b).

References:

- Costa, M., Muniz, M., Negrao, C., Costa, C., Lamarao, M., Morais, L., Junior, J. and Costa, R.. (2013) 'Characterization of *Pentaclethra macroloba* oil', *Journal of Thermal Analysis and Calorimetry*, 16 January 2013 [Online].
- Isaac, C., Mathor, M., Bariani, G., Paggiaro, A., Herson, M., Goldenstein-Schainberg, C., Carrasco, S., Teodoro, W., Yoshinari, N. and Ferreira, M. (2009) 'Pentoxifylline modifies three-dimensional collagen lattice model contraction and expression of collagen types I and III by human fibroblasts derived from post-burn hypertrophic scars and from normal skin', *Burns*, 35 (5), p.701-706.
- Mustoe, T. (2008) 'Evolution of silicone therapy and mechanism of action in scar management', *Aesthetic Plastic Surgery*, 32 (1), p.82-92.
- Nomura, M., Ichimatsu, D., Moritani, S., Koyama, I., Dong, Z., Yokogawa, K. and Miyamoto, K. (2005) 'Inhibition of epidermal growth factor-induced cell transformation and Akt activation by caffeine', *Molecular Carcinogenesis*, 44 (1), p.67-76.
- PCCA (2013a) *PracaSil-Plus*. Available at: <http://www.pccarx.com/pcca-products/pcca-exclusives/bases/PracaSil-plus> (Accessed: 17 May 2013).
- PCCA (2013b) 'Efficacy of PracaSil-Plus in scar therapy treatment: a randomized, double-blind, controlled pilot trial', *Technical Report: 2TR0513*.
- Widgerow, A., Chait, L., Stals, R. and Stals, P. (2000) 'New innovations in scar management', *Aesthetic Plastic Surgery*, 24 (3), p.227-234.
- Yamada, H., Tajima, S., Nishikawa, T., Murad, S. and Pinnell, S. (1994) 'Tranilast, a selective inhibitor of collagen synthesis in human skin fibroblasts', *The Journal of Biochemistry*, 116 (4), p.892-897.



Click the QR to see more PCCA studies and reports.

Case Study: Facial Burn & Diaper Rash

PCCA PracaSil™-Plus

Pediatrics



Summary: PracaSil-Plus, a proprietary anhydrous silicone base, was applied topically on an infant's facial scalding burn and on a toddler's diaper rash, resulting in considerable progress in both pediatric case studies.

Case Description (1): A 5-month-old infant was severely scalded with a liquid on the face resulting in a major second degree burn. Following the incident, PracaSil-Plus was advised to be applied twice daily, in addition to a sterile bacitracin ointment. After eight days, there was a considerable progress of the infant's facial burn, as shown in the figures below.

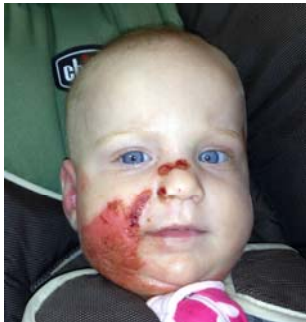

Figure 1. Infant facial burn (before PracaSil-Plus)

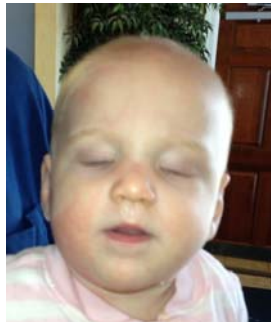

Figure 2. Infant facial burn (8 days after PracaSil-Plus)

Pharmacist Report: Eight days after the treatment, the father came back to my pharmacy with the baby and my staff was about to cry. The father was absolutely blown away with the results and we were, too.

Case Description (2): The caregivers of a 15-month-old toddler suffering from diaper rash had tried several over-the-counter topical products without success. The condition got worse with time resulting in increasing pain and discomfort for the toddler. The caregiver was then advised to apply PracaSil-Plus two to four times per day at diaper change. After 48 hours, there was an overall improvement of the toddler's diaper rash, as shown in the figures below.

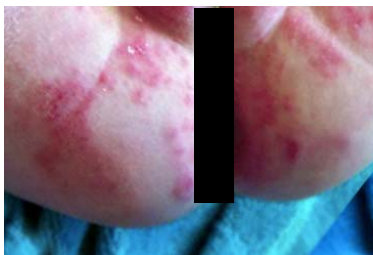

Figure 3. Toddler diaper rash (before PracaSil-Plus)

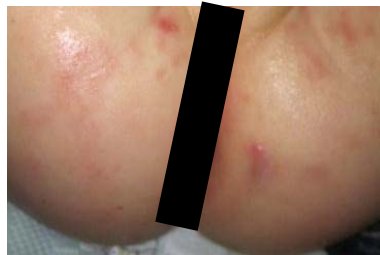

Figure 4. Toddler diaper rash (48 hours after PracaSil-Plus)

Caregiver Report: PracaSil-Plus was applied only twice in the first day and we still got amazing results. It worked so quickly – it took away the pain almost immediately. We are very happy!

Acknowledgements: Case Description (1) was reported by Mark Binkley, a PCCA Member of 30 years. Case Description (2) was reported by the grandmother of the patient, Cathie Berg, a PCCA Member of 27 years. PCCA Science is grateful for the valuable information shared by both Members.

Introduction: PracaSil-Plus is a proprietary anhydrous silicone base designed to be applied topically in scar therapy treatment (PCCA, 2013a). Silicones have been widely used for their occlusion and hydration properties, which are essential in scar management (Widgerow *et al.*, 2000; Mustoe, 2008). PracaSil-Plus also contains Pracaxi oil, extracted from the oilseed plant *Pentaclethra macroloba*, which has several medicinal applications including skin regeneration and healing (Costa *et al.*, 2013). PracaSil-Plus may be used alone or as a base for the incorporation of active substances in scar therapy treatment (PCCA, 2013a).

Research Studies: The efficacy of PracaSil-Plus in scar therapy treatment was evaluated by visual and instrumental methods in an eight-week, randomized, double-blind, controlled pilot trial conducted on eleven adult Caucasian subject volunteers. PracaSil-Plus showed qualitative and quantitative improvements in the following scar attributes: scar length, scar color/pigment intensity, scar texture/smoothness/roughness, and overall appearance in both old scars and new scars (PCCA, 2013b).

References:

- Costa, M., Muniz, M., Negrao, C., Costa, C., Lamarao, M., Morais, L., Junior, J. and Costa, R. (2013) 'Characterization of *Pentaclethra macroloba* oil', *Journal of Thermal Analysis and Calorimetry*, 16 January 2013 [Online].
- Mustoe, T. (2008) 'Evolution of silicone therapy and mechanism of action in scar management', *Aesthetic Plastic Surgery*, 32 (1), p.82-92.
- PCCA (2013a) *PracaSil-Plus*. Available at: <http://www.pccarx.com/pcca-products/pcca-exclusives/bases/PracaSil-plus> (Accessed: 17 May 2013).
- PCCA (2013b) 'Efficacy of PracaSil-Plus in scar therapy treatment: a randomized, double-blind, controlled pilot trial', *Technical Report: 2TR0513*.
- Widgerow, A., Chait, L., Stals, R. and Stals, P. (2000) 'New innovations in scar management', *Aesthetic Plastic Surgery*, 24 (3), p.227-234.



Click the QR to see more PCCA studies and reports.

Case Study: Snake Burn

PCCA PracaSil™-Plus

Veterinary



Summary: PracaSil-Plus, a proprietary anhydrous silicone base, was applied topically on a snake burn and complete healing was achieved with success.

Case Description: A 7-month-old snake (*Python regius* or Ball Python) was burned on the ventral surface while lying on a heated rock. PracaSil-Plus was advised to be applied two times a day but the owner only managed to apply PracaSil-Plus once every other day. Complete healing was achieved with success following 17 days of treatment, as demonstrated in Figures 1 and 2. The owner was confident that if he had applied PracaSil-Plus as directed, great results would have been achieved in 7 days only.

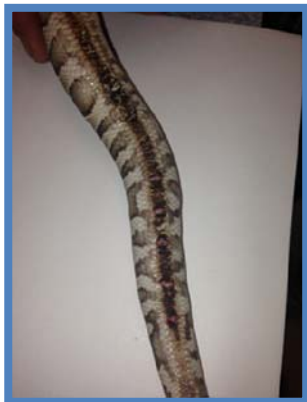

Figure 1.
Snake ventral surface
(before PracaSil-Plus)



Figure 2.
Snake ventral surface
(after PracaSil-Plus)

Acknowledgements: The owner is a PCCA Member who agreed to anonymously share the information included in this veterinary case study. Figures 1 and 2 are courtesy of the PCCA Member. PCCA Science is grateful for the valuable information shared by the Member.

Introduction: PracaSil-Plus is a proprietary anhydrous silicone base designed to be applied topically in scar therapy treatment (PCCA, 2013a). Silicones have been widely used for their occlusion and hydration properties, which are essential in scar management (Widgerow *et al.*, 2000; Mustoe, 2008). PracaSil-Plus also contains Pracaxi oil, extracted from the oilseed plant *Pentaclethra macroloba*, which has several medicinal applications including skin regeneration and healing (Costa *et al.*, 2013). PracaSil-Plus may be used alone or as a base for the incorporation of active substances in scar therapy treatment (PCCA, 2013a).

Research Studies: The efficacy of PracaSil-Plus in scar therapy treatment was evaluated by visual and instrumental methods in an eight-week, randomized, double-blind, controlled pilot trial conducted on eleven adult Caucasian subject volunteers. PracaSil-Plus showed qualitative and quantitative improvements in the following scar attributes: scar length, scar color/pigment intensity, scar texture/smoothness/roughness, and overall appearance in both old scars and new scars (PCCA, 2013b).

References:

- Costa, M., Muniz, M., Negrao, C., Costa, C., Lamarao, M., Morais, L., Junior, J. and Costa, R. (2013) 'Characterization of *Pentaclethra macroloba* oil', *Journal of Thermal Analysis and Calorimetry*, 16 January 2013 [Online].
- Mustoe, T. (2008) 'Evolution of silicone therapy and mechanism of action in scar management', *Aesthetic Plastic Surgery*, 32 (1), p.82-92.
- PCCA (2013a) *PracaSil-Plus*. Available at: <http://www.pccarx.com/pcca-products/pcca-exclusives/bases/PracaSil-plus> (Accessed: 17 May 2013).
- PCCA (2013b) 'Efficacy of PracaSil-Plus in scar therapy treatment: a randomized, double-blind, controlled pilot trial', *Technical Report: 2TR0513*.
- Widgerow, A., Chait, L., Stals, R. and Stals, P. (2000) 'New innovations in scar management', *Aesthetic Plastic Surgery*, 24 (3), p.227-234.



Click the QR to see more
PCCA studies and
reports.

Contact PCCA

 PCCA AUSTRALIA

Unit 1, 73 Beauchamp Road
Matraville NSW 2036 Australia

phone 02.9316.1500

fax 02.9316.7422

www.pccarx.com.au

 PCCA USA

9901 S. Wilcrest Drive
Houston, Texas 77099

phone 800.331.2498 or
281.933.6948

fax 800.874.5760 or
281.933.6627

www.pccarx.com

 PCCA CANADA

744 Third Street
London, ON Canada N5V 5J2

phone 800.668.9453 or
519.455.0690

fax 800.799.4537 or
519.455.0697

www.pccarx.ca